

УДК 616.833.34-089.5-031

B. Tuyakov, Z. Stepien, D. Onichimowski, E. Mayzner-Zawadzka

DISLOCATION OF CATHETERS DURING CONTINUOUS PERIPHERAL NERVE BLOCKS. AN INVISIBLE PROBLEM

*Department of Anaesthesiology and Intensive Care, Clinical Hospital WSS,
Olsztyn, Poland,*

*Department of Anaesthesiology and Intensive Care, Medical Faculty,
University of Warmia and Mazury, Olsztyn, Poland*

УДК 616.833.34-089.5-031

Б. Туяков, С. Степин, Д. Онихимовски, Е. Майзнер-Завацка

ДИСЛОКАЦИЯ КАТЕТЕРОВ ПРИ ПРОДЛЕННЫХ ПЕРИФЕРИЧЕСКИХ НЕРВНЫХ БЛОКАХ. НЕВИДИМАЯ ПРОБЛЕМА

Актуальность. Частота дислокации катетера остается неизвестной. Смещение может вырасти до 30 % и повлиять на качество послеоперационной региональной анальгезии. Производители внедряют все большее число технических решений, которые улучшают оригинальное размещение и обеспечивают потенциальную возможность скорректировать расположение катетера во время послеоперационного обезболивания.

Материалы и методы. Катетер через иглу является хорошим вариантом, чтобы уменьшить смещение периферических нервных катетеров. Новый тип катетера — Certa Катетер имеет оригинальную конструкцию и может быть альтернативой при непрерывных периферических нервных блоках. Дальнейшие исследования являются обязательными. Оптимальный уход, адекватная фиксация, антисептическая техника остаются основными факторами для уменьшения этой проблемы.

Результаты. Клинические данные показали, что проблема смещения катетера при периферических нервных блоках уменьшена. Частота смещения очень высока и может повлиять на качество послеоперационной региональной анальгезии. Причины дислокаций не определены полностью.

Выводы. Катетер через иглу может уменьшить утечку вокруг катетера и увеличить сопротивление. Certa Катетер — новый, перспективный метод и требует дальнейших исследований. Надлежащий уход и внимание остаются основными факторами, снижающими смещение катетеров.

Ключевые слова: региональная анестезия, послеоперационное управление болью, Certa Катетер, дислокация катетера, смещение катетеров, непрерывный периферический нервный блок.

UDC 616.833.34-089.5-031

B. Tuyakov, Z. Stepien, D. Onichimowski, E. Mayzner-Zawadzka

DISLOCATION OF CATHETERS DURING CONTINUOUS PERIPHERAL NERVE BLOCKS. AN INVISIBLE PROBLEM

Relevance. The frequency of catheter dislocation remains unknown. Dislodgement can rise up to 30 % and might affect the quality of postoperative regional analgesia. The manufacturers introduce an increasing number of technical solutions, which improve the original placement and provide the potential possibility to correct the catheter location during a post-operative analgesia.

Materials and methods. The catheter over needle are good option to reduce dislodgement of peripheral nerve catheters. New type of catheter — Certa Catheter has original design and might be an alternative during continuous peripheral nerve blocks. Further studies are guaranteed. Optimal care, adequate fixation, antiseptic technique stay main factors to diminish this problem.

Results. Clinical data showed that the problem of catheter dislodgement by peripheral nerve blocks is underestimated. The frequency of displacement is very high and might affect the quality of postoperative regional analgesia. The reasons of dislocation has been not determined completely.

Conclusions. The catheters over needle can diminish the leakage around the catheter and increase the resistance. The Certa Catheter is a new promising method and further investigations are guaranteed. The proper care and attention stay main factors decreasing dislocation of the catheters.

Key words: regional anaesthesia, post-operative pain management, certa catheter, dislocation of catheter, dislodgement of catheters, continuous peripheral nerve blocks.

Introduction

Despite the wide range of continuous blockade techniques, the frequency of catheter dislocation remains unknown [11; 12]. The dislocation time and mechanisms and influence of passive and active patient movements still need to be precisely identified [10]. In theory, the type of catheter, the placement and fixation method, the anatomical variability and patient movements can have an influence on the efficacy of a blockade [9]. Although multi-modal analgesia is widely performed, the post-operative pain control level is not an optimal catheter displacement indicator [1].

Overview of the Literature

Several authors [1] have sought to measure the frequency of catheter dislocation after the interscalene brachial plexus and femoral nerve blockade. Dislocation, detected by ultrasound, has been noted in 15 % of the blockades. During an interscalene block (ISB), there is a displacement within an interscalene anterior muscle, while in the femoral nerve blockade it has moved inside the inguinal ligament. The position correction can provide technical and hygienic difficulties and the enhancement of local anaesthetic volume is also ineffective when the tip of the catheter lays inside a muscle or a fascia layer. The distance between the skin and the end of a catheter has not been altered even in a dislocation group, so the length of the catheter insertion does not provide sufficient information. An ultrasound monitored fluid spread seems to be an optimal method of a catheter placement control [5; 7; 8]. On the other hand, the catheter insertion length is used as an indicator of correct catheter fixation. The cited study has shown that there is more catheter displacement during a femoral nerve block than an interscalene block (25 % vs 5 %) due to the greater influence of hip movement on the catheter during walking, for example [1]. As there are several post-operative methods of physiotherapy, e. g. immediate

rehabilitation after frozen shoulder surgery or passive motion therapy after knee surgery — the real catheter displacement frequency requires further study. The authors of the study have also shown a significant correlation between the time and the rate of dislocation, which can result from post-operative physiotherapy.

To reduce the frequency of catheter dislodgement, pharmaceutical companies have sought to improve peripheral continuous block equipment [2; 6]. They have introduced an increasing number of technical solutions, which improve the original placement and provide the potential possibility to correct the catheter location during a post-operative analgesia.

A group of authors from Canada [2; 6] evaluated two types of catheters: Catheter over Needle (CON) and Catheter Through the Needle (CTN). They investigated leak pressure around the catheter and the catheter's resistance to pulling forces. Moreover, they noted the possibility of catheter dislocation due to the loss of adhesion of material used to fixate it. A CTN catheter includes a flexible microcatheter which is threaded through a larger diameter needle. A number of various methods to reduce the dislocation problem of CTN catheterization, including the application of adhesive glue and tunnelling the catheter under the skin, were presented. However, these methods require additional procedures and might provoke patient discomfort. In the CON design, the catheter diameter is larger than that of the needle, which might result in a lower risk of a leakage. Compared to CTN, CON presents six times higher forces than hold the catheter to the skin, which reduce a dislocation possibility, when fixated with a single patch. Another CTN problem is the possibility of catheter translocation during a needle withdrawal, whereas the CON design allows to fixate it during this procedure. Moreover, the fact that the skin holds the CON tightly allows the clinician to withdraw the needle with one hand, without moving the catheter forward or backward.

Furthermore, in CON design, the injectate spread used to verify the final localization of the catheter is able to be observed before the needle withdrawal, in contrast to CTN, where the catheter is located beyond the needle and the final catheter tip localization can be altered.

A group of Danish anaesthetists [3] have proposed another solution. They presented a large suture with a catheter attached to the base of the needle [4]. The curved shape of the needle allows a precise needle insertion and catheter adjustment, guided by ultrasound (Fig. 1). There are two holes in the catheter, from which the local anaesthetic ex-

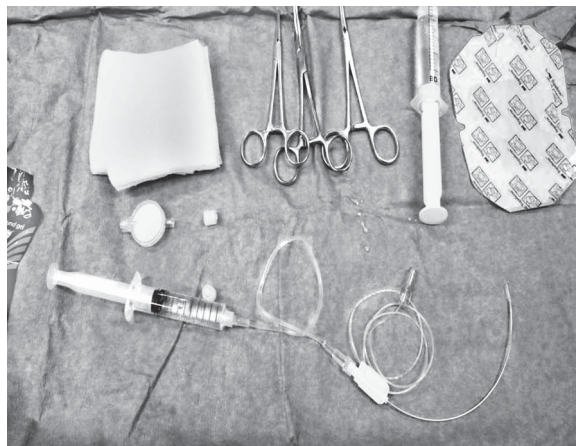

Fig. 1. Certa Catheter Set with curve needle and echogenic catheter

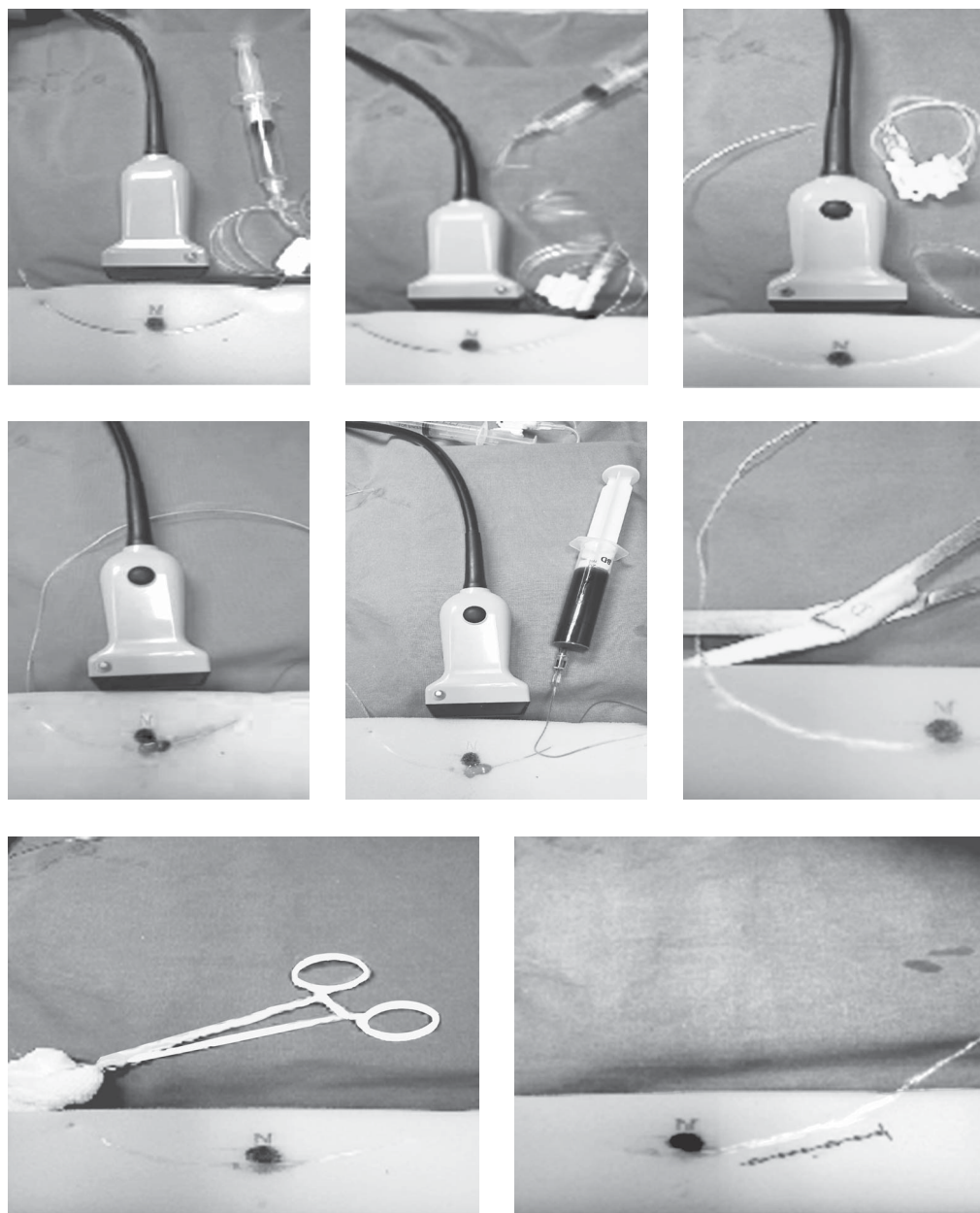


Fig 2. The steps of insertion and removal Certa Catheter.

The needle with attached catheter is inserted through tissues in close the nerve under ultrasound and then, it advanced and emerged through a skin exit hole. The hub is detached from the needle. The orificies for local anesthetic delivery are localized close the targeted nerve, next to the last echogenic markings on the catheter. The catheter is replaced to the proper site by pulling both end under ultrasound. The needle is cut off from the catheter. Both ends of catheter are fixed to the skin.

Removal of the catheter: distal end was cut off near the skin with steril technique and the catheter is pulled off on the proximal end

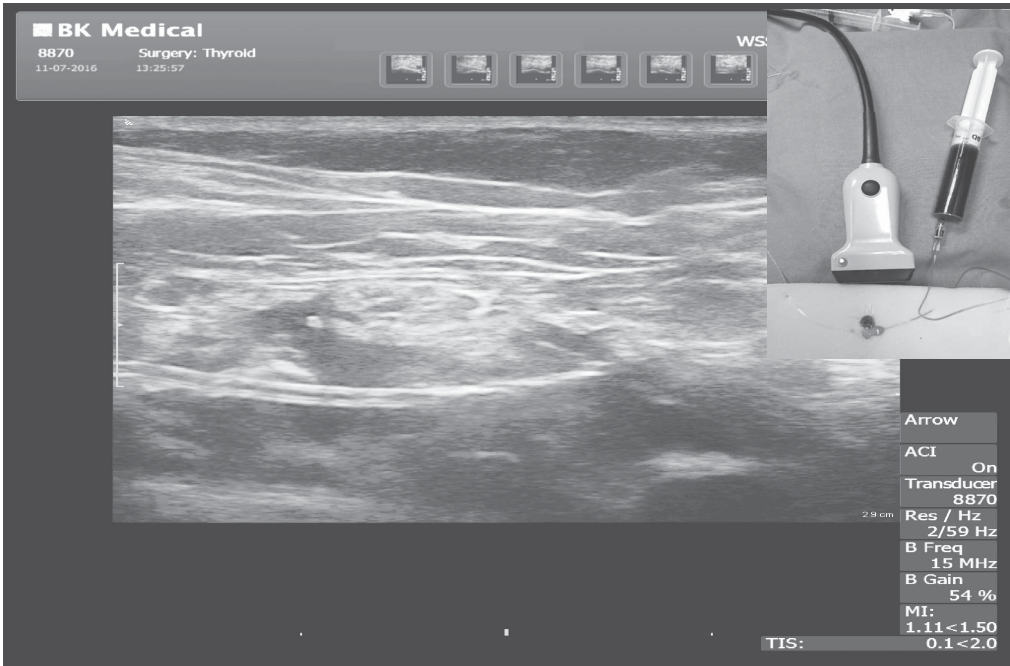


Fig. 3. Sciatic popliteal fossa block. The Certa Catheter is placed close to nerve. The solution is spreading through orificies on the boundary visible and less echogenic parts of the catheter

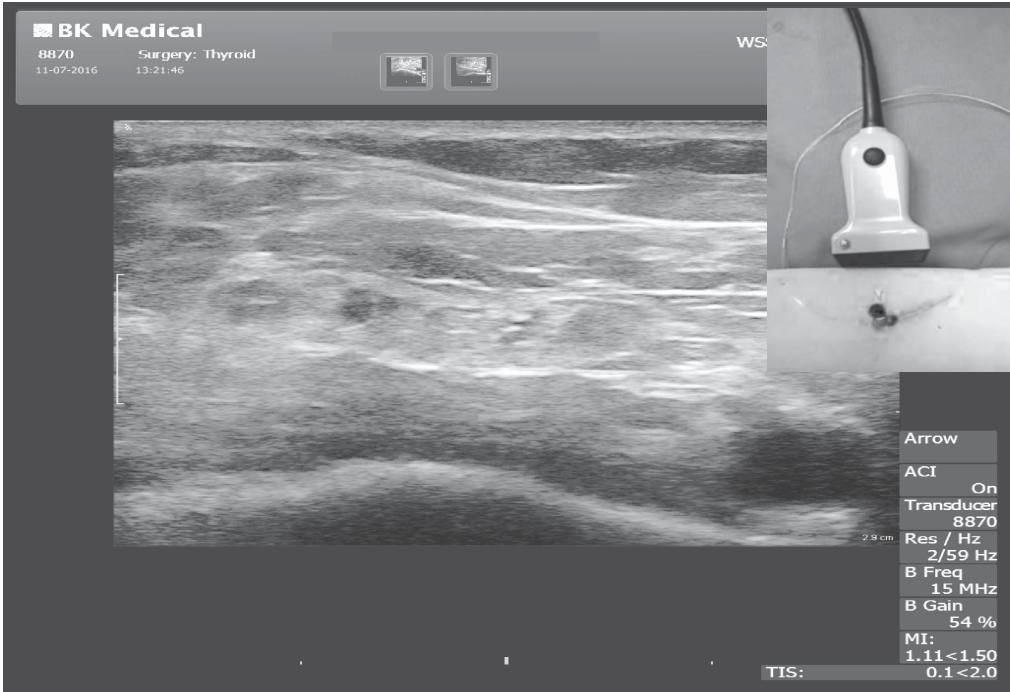


Fig. 4. Certa Catheter with echogenic markings. Red arrows — air-bubbles embedded into distal blinded part of the catheter

its, which are sited at a junction in the catheter that is visible on ultrasound (Fig. 2). This design enables precise local anaesthetic insertion close to the nerve [5] (Fig. 3). Primary placement and subsequent repositioning are achieved by pulling either of ends of the catheter. Both ends are attached to the skin by a sterile bandage. The catheter is guided by the needle thanks to its curvature and stiffness. In superficial blockades, the needle can be easily directed by holding a hub. The part of the catheter which lays behind the holes is invisible on ultrasound and is blindly ended (Fig. 4). In the cadaver study, the adherence to the femoral nerve, the saphenous nerve and the sciatic nerve from various approaches has been evaluated. The authors have admitted the superiority of the curved needle over the straight needle thanks to its higher echogenicity and better manoeuvrability. The curved needle tip, while being held in the air, changes its position by twisting the hub, in contrast to the straight needle, where the tip stays in the same position. However, practising the use of the curved needle is essential, as the orientation of the needle on insertion and exit might be problematic. The nerve should lie within the radius of curvature to enable its skin exit. A small convex ultrasound probe could help to shorten the learning period.

However, some nerve approaches could be limited due to the possibility of tissue damage, as a catheter may act as a string. In view of this fact, it is recommended to place the catheter anterior to nerves and arteries. This situation might concern the interscalene block approach, where placing the catheter between C5 and C6 roots could be risky. In the femoral nerve approach, the catheter should be placed anterior to the femoral artery and nerve, omitting the saphenous nerve. In the adductor canal block, it should be situated anterior and medial to the saphenous nerve and the femoral artery. Such an approach could preclude nerve damage in case of incidental catheter movement [5].

The described technique might be useful not only in nerve block extremities, but also abdominal and pectoral nerve blocks [5; 7]. On the other hand, this method might increase the infection rate which could result from breaching the skin in two places and passing through more tissue by the catheter. Moreover, repositioning of the catheter will pull one end back under the skin. The diameter of this catheter is slightly larger than that of the needle, which should reduce the possibility of leakage. A local anaesthetic leak far from the nerve or in the skin area could result in a lack of an analgetic effect. The risk of local anaesthetic leak is greater in the Catheter Through Needle type,

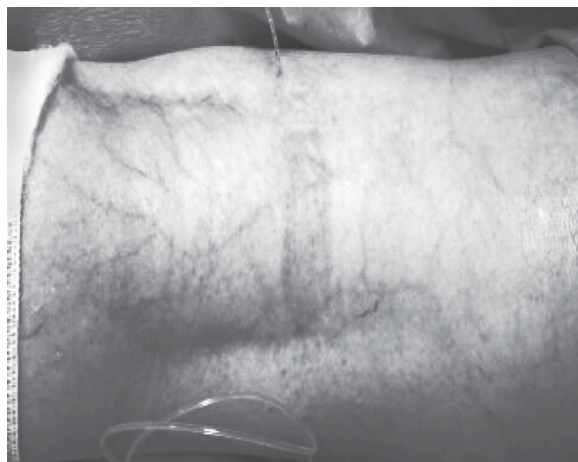

Fig. 5. Sciatic popliteal fossa block. Both ends of Certa Catheter after insertion. Reposition after displacement is possible by pulling either of ends of the catheter

due to a larger needle than catheter diameter than in the Catheter On Needle technique.

The success rate of Certa Catheter insertion was assessed with short axis and long axis approach for adductor — canal block [8]. In this randomised blind — assessor trial with 16 volunteers (32 catheters, together) the authors recorded primary and second dislodgement of catheter and the possibility of repositing by displacement. 100 % short-axis approach and 94 % long-axis approach were successful, 1 catheter by short-axis approach and 3 catheters by long-axis approach were displaced on the second day. All catheters were repositing except 1 catheter. Distal end of one catheter localized under skin and it precluded from the reposition.

A Retrospective observational study [11] was carried out on 28 patients with insertion of Certa Catheter™ (Ferrosan Medical Devices Sp. z.o.o.). Visibility of the needle, catheter, dislocation (distance from the hole of catheter to the nerve during insertion and after 24 h., the length of distal part catheter), leakage, skin redness, local site infection and nerve injury were perceived. Continuous adductor canal block, popliteal fossa block, subgluteal sciatic nerve block, serratus plane block were performed. Only 2 patients were excluded from the observation. In one case by subgluteal sciatic nerve block authors observed the blood in the catheter after 6 hours of perineural infusion.

In the second case, the displacement of catheter occurred after tourniquet deflating.

Postoperative analgesia was successful in all 26 patients (NRS 1–4 points). Visibility was 3–4 points (mean 3, 8). Dislocation after 24 h was 8 ± 4 mm. Skin redness — 2 cases.

There was no local site infection and nerve injury after removing Certa Catheter™. The authors concluded, that Certa Catheter™ can be used successfully and safely. Postoperative analgesia may be successful in most of the patients. Visibility of the catheter is very high and a design allows correct positioning of the catheter. Dislocation may be restricted due to better anchoring of this type of catheter.

Conclusions

Clinical data showed that the problem of catheter dislodgement by peripheral nerve blocks is underestimated. The frequency of displacement is very high and might affect the quality of postoperative regional analgesia. The reasons of dislocation has been not determined completely. The catheters over needle can diminish the leakage around the catheter and increase the resistance. The Certa Catheter is new promising method and further investigations are guaranteed. The proper care and attention stay main factors decreasing dislocation of the catheters.

REFERENCES

1. Marhofer D. Dislocation rates of perineural catheters: a volunteer study. *Br J Anaesth*. 2013 Nov; 111(5): 800-6.
2. Tsui B.C.H. et al. Less leakage and dislodgement with a catheter-over-needle versus a catheter-through-needle approach for peripheral nerve block. *Can J Anesth* 2012; 59: 655-661.
3. Rothe C. et al. A novel suture method to place and adjust peripheral nerve catheters *Anaesthesia* 2015, July; 70 (7): 791-6.
4. Rothe C. et al. A Novel Concept and Catheter for Continuous Peripheral Nerve Blocks — Ultrasound and Magnetic Resonance Imaging Evaluation of Initial Placement and Readjustment in Fresh Cadavers. Spring 2015 Abstract ASRA 40th Annual Regional Anesthesia and Acute Pain Medicine Meeting, May 14-16, 2015.

5. Rothe C. et al. A novel concept for continuous peripheral nerve blocks. Presentation of a new ultrasound-guided device. *Acta Anaesthesiologia Scandinavica* 2015; Feb; 59 (2): 232-7.
6. Ben Tsui T. Catheter-over-needle method reduces risk of perineural catheter dislocation. *BJA* 2013: 759-760.
7. Tuyakov B. et al. Continuous peripheral nerve block (CPNB) with the use of Certa Catheter™. Case series, 35th Annual ESRA Congress 2016, Maastricht, The Netherlands.
8. Lyngeraa T.S. et al. Primary placement and secondary repositioning of a new suture-method catheter for continuous adductor canal block, 35th Annual ESRA Congress 2016, Maastricht, The Netherlands.
9. Hauritz R.W. et al. Displacement of popliteal sciatic nerve catheters after major foot and ankle surgery. *BJA* 2016: 220-227.
10. Iffeld B.M. Continuous Peripheral Nerve Blocks in the Hospital and at Home. *Anesthesiology Clin* 2011; 29: 193-211.
11. Machia A.T., Brian M. Iffeld. Continuous peripheral nerve blocks in the ambulatory setting: an update of the published evidence. *Curr Opin Anesthesiol.* 2015; 28: 648-655.
12. Aguirre Jose, Alicia DelMoral, Irina Cobo, Alain Borgeat and Stephan Blumenthal. The Role of Continuous Peripheral Nerve Blocks. Review Article. *Anesthesiology Research and Practice* 2012: 1-20.

Submitted 19.02.2017

Reviewer MD, prof. O. O. Tarabrin