

I. I. Chesov

**ASSESSMENT OF SPREAD AND  
DISTRIBUTION PATTERN OF CONTRAST  
DYE INJECTED UNDER ULTRASOUND  
GUIDANCE IN THE TRANSVERSE ABDOMINAL  
PLANE. A CADAVERIC STUDY**

*“Nicolae Testemitanu” State University of Medicine and Pharmacy,  
“Valeriu Ghereg” Department of Anesthesia and Reanimatology,  
Chisinau, Republic of Moldova*

**УДК 616-08**

**И. И. Кесов**

**ОЦЕНКА РАСПРОСТРАНЕНИЯ И РАСПРЕДЕЛЕНИЯ КОНТРАСТ-  
НОГО КРАСИТЕЛЯ, ВВОДИМОГО ПОД УЛЬТРАЗВУКОВЫМ КОНТРО-  
ЛЕМ В ПОПЕРЕЧНУЮ АБДОМИНАЛЬНУЮ ПЛОСКОСТЬ. АНАТОМИ-  
ЧЕСКОЕ ИССЛЕДОВАНИЕ**

**Введение.** Оптимальный объем и концентрация вводимого анестетика остаются спорными в случае ТАР-блока.

**Цель** исследования состояла в оценке распространения красителя, вводимого в поперечную абдоминальную плоскость.

**Методы.** Исследование было проведено на 15 трупах, распределенных на 3 группы в зависимости от объема вводимого красителя (10, 20 и 40 мл). Степень распространения красителя определялась путем рассечения брюшной стенки.

**Результаты.** Выявлены значительные различия в распределении красителя после инъекции 10 мл по сравнению с 20–40 мл ( $p < 0,001$ ). Существенных различий в распределении красителя после инъекции 20 и 40 мл не обнаружено ( $p > 0,05$ ). Установлена сильная положительная корреляция между степенью распространения и объемом вводимого красителя.

**Вывод.** Распространение красителя было сходным при введении объема 20 и 40 мл, значительно превышая распространение после инъекции объема 10 мл.

**Ключевые слова:** ТАР-блок, трупное исследование, распространение красителя.

**UDC 616-08**

**I. I. Chesov**

**ASSESSMENT OF SPREAD AND DISTRIBUTION PATTERN OF  
CONTRAST DYE INJECTED UNDER ULTRASOUND GUIDANCE IN THE  
TRANSVERSE ABDOMINAL PLANE. A CADAVERIC STUDY**

**Introduction.** Optimal volume and concentration of injected local anesthetic, as well as sensory block extension remain controversial in case of TAP-block.

**The aim** of the present study was to assess the extent and the pattern of dye (methylene blue) spread, injected in the transverse abdominal plane on fresh un-fixed cadavers.

**Methods.** The study was conducted on 15 fresh unembalmed. Cadavers were randomly assigned into 3 equal groups, depending on the amount of dye injected into transverse abdominal area (10, 20 and 40 mL). An ultrasound-guided injection of dye (methylene blue 1%) into the TAP plane was performed for each hemi-abdominal wall. The extent of spread within the TAP plane was determined by detailed dissection of the hemi-abdominal wall. The cranio-caudal and medio-lateral distribution of dye was assessed for every single cadaver bilaterally.

**Results.** The results of present cadaveric study demonstrate significant differences in the dye distribution after injection of 10 mL methylene blue in the transverse abdominal plane, compared with 20 to 40 mL of contrast medium ( $p < 0.001$ ). At the same time, there were no significant differences in the distribution of the cranial-caudal and medio-lateral spread of dye after injection of 20 and 40 ml into the transverse abdominal area ( $p > 0.05$ ). A strong positive correlation was found between the cephalo-caudal and medio-lateral extent of methylene blue and the volume of dye injected in the transverse abdominal area.

**Conclusion.** Our results suggest that 20 mL of contrast dye injected into transverse abdominal space provide significant larger spread in cranial-caudal and medio-lateral distance than the volume of 10 mL. At the same time, the spread of contrast dye was similar for volumes of 20 and 40 mL. The 20 mL may be an optimal volume of local anesthetics used for TAP block.

**Key words:** TAP-block, cadaveric study, spread of dye.

### **What is Already Known on This Subject?**

Transversus abdominis plane block (TAP-block) is a technique of postoperative regional analgesia, first described in 2001 by Rafi A. Ultrasound-guided TAP-block gain popularity in recent. It has been shown to be effective in reducing postoperative pain after lower and upper abdominal surgery. A series of studies have examined various concentrations and volumes of local anesthetics used for TAP-block [1–3]. Often, clinicians inject a volume of 15–30 mL up to 60 mL of local anesthetic, in different concentrations, when performing TAP block, but high doses means an increased risk of local anesthetics toxicity [4].

### **What is not Known Yet about the Topic?**

Still, there are concerns related to the optimal volume, concentration of the local anesthetic solution (LA) used for TAP-block, as well as sensory block extension.

### **What is New in This Article?**

Obviously, our data suggest that there is no differences in the maximum cephalo-caudal and medio-lateral spread of the dye in the transversus abdominal plane after injection of a volume of 40 and 20 mL. In the same time, the spread of contrast dye in transverse abdominal plane space is significant smaller after injection of a volume of 10 mL. Probably, volume of 20 mL may be an optimal volume of local anesthetics used for TAP-blocks.

### **Introduction**

Insufficiently controlled postoperative pain is associated with a variety of undesirable postoperative consequences, including lung and heart complications, distress and suffering, longer hospital stay of patients. Abdominal operations, by either laparotomy or laparoscopy, are accompanied by significant postoperative pain. Abdominal transverse

plane block is a relatively new technique for anesthetizing nerves after abdominal surgery, with the aim of improving postoperative comfort and satisfaction. Existing studies have demonstrated that TAP-block provides effective analgesia, especially in the T10-L1 dermatomes, being recommended for use after lower abdominal and gynecological operations [5; 6].

Several TAP-block techniques are described in the literature, but the optimal volume and concentration of local anesthetic injected and sensory block extension remain controversial [5]. Although cadaveric studies are not without challenges, such as the availability and source of cadavers, they remain a foundation for understanding regional anesthesia, especially when talking about peripheral nerve blocks [7; 8].

**The aim** of the present study was to investigate the extent and the pattern of dye (methylene blue) spread, injected under ultrasound guidance in the transverse abdominal plane on fresh unfixed cadavers. The anatomic study was conceptualized to test the hypothesis that different volumes of contrast dye injected under ultrasound guidance in the transverse abdominal area, influences the pattern and the extent of its spread.

### **Material and Methods**

Approval was obtained from the Research Ethics Committee of the “Nicolae Testemitanu” State University of Medicine and Pharmacy, Chisinau, Moldova (Protocol Nr. 54 of 06/25/2014). The study was conducted on 15 fresh unembalmed cadavers without previous surgery/trauma to the abdomen: 11 males and 4 females. Cadavers were randomly assigned into 3 equal groups, depending on the amount of dye injected into transverse abdominal plane (10, 20 and 40 mL). Anthropometric data were collected for each specimen. The unembalmed adult cadaveric specimens were obtained from the Department of Intensive Care, Institute of Emergency Medicine, Chisinau, Republic of Moldova. Written consent signed by the caregiver/legal representative of the deceased was obtained in each case. Bilateral injection of dye into the transverse abdominal plane was performed prior to cadaveric dissection. Over all thirty TAP-blocks were performed. Dissections of 30 cadaveric hemi-abdominal walls were done. The sequence of the study was as follows. Each cadaver was placed in a supine position. First, an ultrasound scan was performed to identify the muscular layers of abdominal wall and to define the transverse abdominal plane bilaterally. A portable ultrasound machine (Mindray Ultrasound Diagnostic System M7, Shenzhen Mindray Bio-Medical Electronics CO., LTD, Nanshan, Shenzhen, R. P. China), with a 12 MHz linear probe was used for all procedures. The ultrasound probe was positioned on the lateral abdominal wall cephalad to the iliac crest and caudal to the costal margin. An ultrasound-guided injection of dye (methylene blue 1%) into the TAP plane was performed for each hemi-abdominal wall, through 18 gauge Vaso-fix Safety catheter needle (B. Braun Melsungen AG 34209 Melsungen Germany) using an in-plane mid-axillary approach. After the dye injection, its extent of spread within the TAP was determined by detailed dissection of the hemi-abdominal wall. The cadavers were dissected 6–12 hours later in layers from superficial to deep. The cranio-caudal and medio-lateral distribution of dye was measured and described for each of the cadavers bilaterally. The relationship between the distance measured and the injected volume was determined. Descriptive statistics were used to report the anthropometric characteristics of cadaveric specimens, and the extent of injected dye. For multiple comparison one way ANOVA was used, by pairs post-hoc analysis Duncan test was applied. Pearson correlation coefficient was used to correlate the spread of contrast dye with the volume injected. Data are presented as mean (SD) and median (interquartile range). SPSS 17.0.1 was used

as statistical software (IBM Inc., Armonk, NY);  $p < 0.05$  was considered as statistically significant.

## Results

All 15 cadavers were examined bilaterally. Thus, 30 hemi-abdominal (10 per group) walls were successfully injected and dissected. The cadavers' mean age at death was  $(75.3 \pm 4.34)$  years, with a range between 66 and 81 years. 11 cadavers (73.33%) were male and 4 cadavers (26.67%) were female. Body weight was  $(75.5 \pm 6.5)$  kg, height  $(169.4 \pm 4.8)$  cm, and mean body mass index  $(25.9 \pm 2.8)$  (range 22–32). There was no statistically significant difference between the groups in terms of demographic or anthropometric characteristics ( $p > 0.05$ ). Specimens' data are showed in Table 1.

Both cephalo-caudal and medio-lateral spread of dye was observed in all cadavers. The extent of transverse abdominal space staining in cephalo-caudal and medio-lateral directions was in relation to injected volumes, as shown in Fig. 1.

The average length of the contrast dye distribution in the cephalic-caudal dimension was  $(12.8 \pm 1.54)$  cm (95% CI 11.7 to 13.9) for the 40 mL methylene blue injection, and  $(11.75 \pm 1.68)$  cm (95% CI 10.5 to 13.0) for the 20 mL methylene blue injection,  $p > 0.05$ . After 10 mL methylene blue injection in the transverse abdominal place, average cephalo-caudal extension of dye was  $(6.20 \pm 0.88)$  cm, being significant lower than for volumes of 40 and 20 ml (95% CI 5.5 to 6.8),  $p = 0.00006$  and  $p = 0.00014$ , respectively. Characteristics of spread of injected dye in the transverse abdominal space are shown in Table 2.

No significant difference could be detected between the medio-lateral spread of 40 ml —  $(9.60 \pm 2.01)$  cm (95% CI 8.11 to 10.98) and 20 mL —  $(10.2 \pm 1.81)$  cm (95% CI 8.90 to 11.5) of methylene blue in the transverse abdominal plane ( $p > 0.05$ ). At the same time, the medio-lateral contrast dye extension after 10 mL methylene blue injection in the transverse abdominal plane was significantly less comparing with 40 mL and 20 mL injections ( $p = 0.00015$  and  $p = 0.000065$ , respectively).

As shown in Fig. 2, strong correlation was found between the cephalo-caudal and medio-lateral extent of methylene blue and the volume of dye injected in the transverse abdominal area ( $R^2 = 0.607$ ,  $p = 0.00001$  and  $R^2 = 0.321$ ,  $p = 0.003$ , respectively).

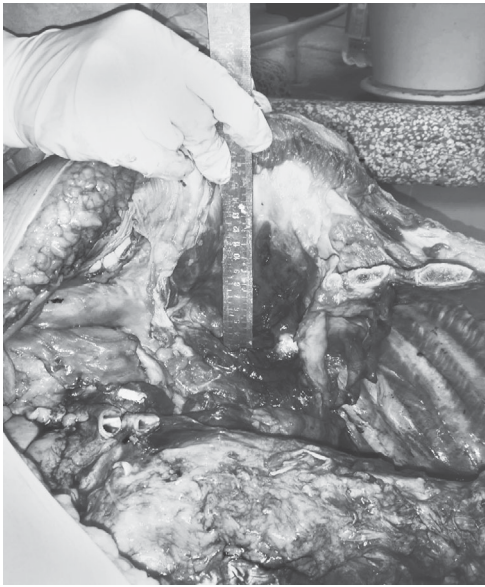The results of present cadaveric study demonstrate significant differences in the dye distribution after injection of 10 mL methylene blue in the transverse abdominal plane, compared with 20 to 40 mL of contrast medium ( $p < 0.001$ ). At the same time, there were no significant differences in the distribution of the cranial-caudal and medio-lateral spread of dye after injection of 20 and 40 mL into the transverse abdominal area ( $p > 0.05$ ).

Table 1

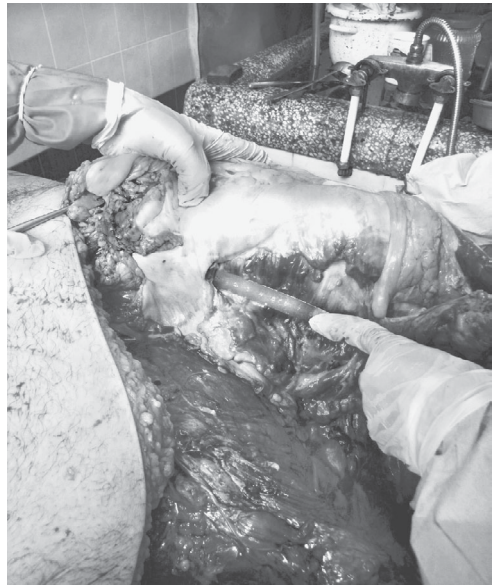### Patients Characteristics at the Time of Death, n=15)

Characteristics	Group 1 (10 mL), n=5	Group II (20 mL), n=5	Group III (40 mL), n=5
Age, years (M±DS)	75.8±2.7*	75.2±5.6*	78.0±5.7*
Weight, kg (M±DS)	73.6±7.1*	75.0±7.1*	77.5±5.2*
Height, cm (M±DS)	170.6±2.4*	168.4±4.6*	169.2±6.9*
BMI, kg/mI (M±DS)	24.8±1.8*	25.8±2.8*	27.0±3.7*
Male/Female, n	3/2	4/1	4/1

Note. Data are presented as Mean±SD or number; BMI — Body Mass Index; \* —  $p > 0.05$ .



a



b

Fig. 1. Photograph of dissection specimens. Spread of the dye in the transversus abdominal plane following 10 mL (a) and 40 mL (b) methylene blue injection

A strong positive correlation was found between the cephalo-caudal and medio-lateral extent of methylene blue and the volume of dye injected in the transverse abdominal area.

**Discussion.** After the initial description of the TAP block technique by A. Rafi (2001), numerous studies have emphasized its value [9–11]. The TAP-block has been shown to be effective in reducing postoperative pain after lower and upper abdominal surgery.

A series of studies have examined various concentrations of local anesthetics administered during the procedure of TAP-blocks [1–3]. A. Rafi (2001) described the use of 20 ml of local anesthetic for each hemi-abdomen for postoperative analgesia. J. McDonnell et al. (2004) reported the administration of 20 mL of lidocaine 0.5% on either side of the abdomen, in healthy volunteers during the TAP block. Most doctors usually inject a total of 15–30 mL to 60 mL of local anesthetic, in different

Table 2  
Characteristics of spread of injected dye (10, 20 and 40 ml 1% methylene blue) in the transverse abdominal plane, cm

Contrast dye volume	Dye distribution, cm	
	Cephalo-caudal spread	Medio-lateral spread
10 mL, n=10		
max	8	7
min	4,5	4,5
mean	6,20±0,88*	5,75±0,86*
20 mL, n=10		
max	15	13
min	9	7
mean	11,75±1,68*	10,20±1,81*
40 mL, n=10		
max	16	14
min	11	7
mean	12,80±1,54*	9,60±2,01*

Note. \* — values are presented as mean±SD.

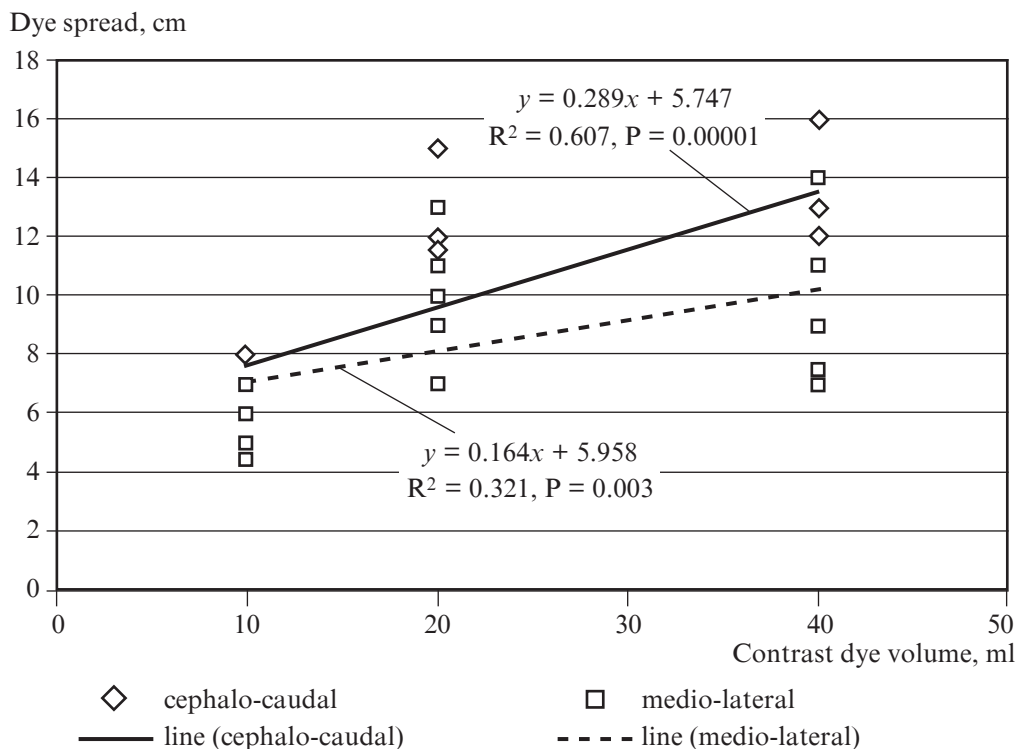


Fig. 2. Correlation between the cephalo-caudal and medio-lateral spread of methylene blue and the volume of dye injected in the transverse abdominal plane

concentrations, when performing TAP-block, but high doses can carry an increased risk of toxicity [4].

Cadaveric studies provide a viable option for practicing US imaging for peripheral blocks [8]. A number of important cadaver studies in adults that offer important insights into peripheral blocks has been reported. M. Barrington et al. (2009) injected 5 mL of contrast dye into human cadavers under ultrasound guidance in order to perform sub-costal TAP-block. After cadaver's dissection, the authors found that single injections covered dermatomes T9–T10, whereas multiple injections covered nerves T8–T11 [12]. J. McDonnell et al. (2007) conducted a cadaveric study to evaluate the distribution of methylene blue injected into the transversus abdominis plane via the triangles of Petit [13]. The authors found an equal spread of contrast within the TAP when using 0.3 and 0.6 mL/kg. T. Tran et al (2009) injected 20 ml of aniline blue dye (0.25% in distilled water) into the TAP under ultrasound guidance, above the iliac crest in the mid-axillary line in cadavers. After dissection, dye was seen distributed between the iliac crest, costal margin, and rectus muscle with an average area of 45 cm<sup>2</sup>. Segmental nerves involved in the dye were T10, T11, T12, and L1 [14]. T. Murouchi et al. (2013) conducted a cadaveric study to evaluate the spread of dye after ultrasound-guided subcostal and mid-axillary transversus abdominis plane block. Authors injected 10 mL of dye on each hemi-abdomen and found the involvement of T7, T8–11, T12, and L1 nerves [15].

The results of our cadaveric study showed that the spread of dye was different depending on the volume of injected contrast. A strong positive correlation was demon-

strated between the volume of contrast medium injected into transverse abdominal area and cranio-caudal or medial-lateral extent of its distribution. At the same time, our results showed a similar distribution of the contrast dye in the transverse abdominal plane after injection of volumes of 20 and 40 mL, presenting a potential utility in calculating doses and concentrations of local anesthetic used during ultrasound-guided TAP blocks in patients undergoing abdominal surgery.

This anatomic study is the first of this type in the Republic of Moldova, where the spread of contrast dye injected into the transverse abdominal space under ultrasound guidance has been investigated by anatomical dissection.

Our study has several limitations. Being a cadaveric study, the way in which fluid passes through, the fascial planes, the echogenicity of tissues may be different in real patients. Tissue inflammation and surgical incision in patients undergoing abdominal surgery could influence the pattern of spread of local anesthetic injected into the TAP-block. One limitation can be considered the relatively small sample size. Thus, the present anatomic study results may serve only to support a hypothesis. It is of course the fact that actual cadaveric study results need to be confirmed in human studies, including clinical effect of TAP-block and satisfaction of patients, surgeons and anesthesiologists. This pre-clinical study may be helpful for determining an appropriate volume for ultrasound-guided TAP-block in patients undergoing abdominal surgery.

### Conclusion

The findings of our anatomic study may help the understanding of injected dye spread following ultrasound-guided TAP injections. Our results suggest that 20 mL of contrast dye injected into transverse abdominal space provide significant larger spread in cranial-caudal and medio-lateral distance than the volume of 10 mL. At the same time, the spread of contrast dye was similar for volumes of 20 and 40 mL. Thus, our findings suggest that the volume of 20 mL may be an optimal volume of analgesia during TAP blocks in patients after abdominal surgery. Further in vivo studies are needed to investigate the minimum volume of ultrasound-guided injected contrast required to cause a sensory blockade of the anterior abdominal wall.

### Disclosure

The author declares no conflicts of interest. This study has received no financial support.

### Acknowledgments

The author is grateful to Dr. Prof Adrian Belii and Dr. Corina Cardaniuc for their continued support and help in the review of this manuscript.

### ЛІТЕРАТУРА

1. *Latzke D.* Pharmacokinetics of the local anesthetic ropivacaine after transversus abdominis plane block in healthy volunteers / D. Latzke, P. Marhofer, S. Kettner // *Eur J Clin Pharmacol.* – doi: 10.1007/s00228-011-1139-8.
2. *Plasma ropivacaine concentrations after ultrasound-guided transversus abdominis plane block* / J. Griffiths, F. Barron, S. Grant [et al.] // *Br J Anaesth.* – 2010. – № 105. – P. 853–856.
3. *Kato N.* Serum concentration of lidocaine after transversus abdominis plane block / N. Kato, Y. Fujiwara, M. Harato // *J Anesth.* – 2009. – № 23. – P. 298–300.
4. *Patterns, Dermatomal Anesthesia, and Ropivacaine Serum Concentrations After Bilateral Dual Transversus Abdominis Plane Block* / J. Børglum, K. Jensen, A. F. Christensen [et al.] // *Regional Anesthesia and Pain Medicine.* – 2012. – № 3. – P. 294–301.

5. *Clinical Implications of the Transversus Abdominis Plane Block in Adults* / M. J. Young, A. W. Gorlin, V. E. Modest, S. A. Quraishi // *Anesthesiol Res Pract.* – 2012. – № 1. – P. 645–731.
6. *Perioperative transversus abdominis plane (TAP) blocks for analgesia after abdominal surgery* / A. Charlton, M. Cyna, P. Middleton, J. D. Griffiths // *Cochrane Database of Systematic Reviews.* – 2010. – № 8. – P. 77–75.
7. *Lonnqvist P. A. Anatomical dissections are not obsolete. Cadaver studies can still provide important information for regional anaesthesia* / P. A. Lonnqvist, A. Bosenberg // *Eu J Anesthesiolog.* – 2014. – № 31. – P. 303–304.
8. *Ultrasound imaging in cadavers: training in imaging for regional blockade at the trunk* / B. Tsui, D. Dillane, J. Pillay, A. Walji // *Canadian J Anesth.* – 2008. – № 55 (2). – P. 105–111.
9. *Conaghan P. Efficacy of transversus abdominis plane blocks in laparoscopic colorectal resections* / P. Conaghan, C. Maxwell-Armstrong, N. Bedforth // *Surg Endosc.* – 2010. – № 24. – P. 2480–2484.
10. *Mukhtar K. Transversus abdominis plane block for renal transplant recipients* / K. Mukhtar, I. Khattak // *Br J Anaesth.* – 2010. – № 104. – P. 663–667.
11. *Niraj G. Analgesic efficacy of ultrasound-guided transversus abdominis plane block in patients undergoing open appendectomy* / G. Niraj, A. Searle, M. Mathews // *Br J Anaesth.* – 2009. – № 103. – P. 601–606.
12. *Spread of injectate after ultrasound-guided subcostal transversus abdominis plane block: a cadaveric study* / M. J. Barrington, J. J. Ivanusic, W. M. Rozen, P. Hebbard // *Anaesthesia.* – 2009. – № 64. – P. 745–795.
13. *Transversus abdominis plane block: a cadaveric and radiological evaluation* / J. G. McDonnell, B. D. O'Donnell, T. Farrell [et al.] // *Reg Anesth Pain Med.* – 2007. – № 32. – P. 399–404.
14. *Determination of spread of injectate after ultrasound-guided transversus abdominis plane block: a cadaveric study* / T. Tran, J. Ivanusic, P. Hebbard, M. Barrington // *Br J Anaesth.* – 2009. – № 102. – P. 123–130.
15. *Ultrasound-guided subcostal and midaxillary transversus abdominis plane block: a cadaveric study of the spread of injectate* / T. Murouchi, M. Yamauchi, E. Gi [et al.] // *Masui.* – 2013. – № 62 (1). – P. 60–63.

## REFERENCES

1. Latzke D., Marhofer P., Kettner S. et al. Pharmacokinetics of the local anesthetic ropivacaine after transversus abdominis plane block in healthy volunteers [published online ahead of print October 27, 2011]. *Eur J Clin Pharmacol.* doi: 10.1007/s00228-011-1139-8.
2. Griffiths J., Barron F., Grant S., Bjorksten A., Hebbard P., Royse C. Plasma ropivacaine concentrations after ultrasound-guided transversus abdominis plane block. *Br J Anaesth.* 2010; 105: 853Y856.
3. Kato N., Fujiwara Y., Harato M. et al. Serum concentration of lidocaine after transversus abdominis plane block. *J Anesth.* 2009; 23: 298Y300.
4. Børglum J., Jensen K., Christensen A.F., Hoegberg L., Johansen S., Lonnqvist P.A., Jansen T. Patterns, Dermatomal Anesthesia, and Ropivacaine Serum Concentrations After Bilateral Dual Transversus Abdominis Plane Block. *Regional Anesthesia and Pain Medicine* & Volume 37, Number 3, May-June 2012. P 294-301.
5. Young M.J., Gorlin A.W., Modest V.E., Quraishi S.A. Clinical Implications of the Transversus Abdominis Plane Block in Adults. *Anesthesiol Res Pract.* 2012; 2012: 731645. doi: 10.1155/2012/731645
6. Charlton A., Cyna M., Middleton P., Griffiths J.D. Perioperative transversus abdominis plane (TAP) blocks for analgesia after abdominal surgery, *Cochrane Database of Systematic Reviews*, vol. 8, Article ID CD007705, 2010.



7. Lonnqvist P.A., Bosenberg A. Anatomical dissections are not obsolete. Cadaver studies can still provide important information for regional anaesthesia. *Eu J Anesthesiolog* 2014; 31: 303-304.
8. Tsui B., Dillane D., Pillay J., Walji A. Ultrasound imaging in cadavers: training in imaging for regional blockade at the trunk. *Ccnadian J Anesth* 2008; 55(2): 105-111.
9. Conaghan P., Maxwell-Armstrong C., Bedforth N. et al. Efficacy of transversus abdominis plane blocks in laparoscopic colorectal resections. *Surg Endosc.* 2010; 24: 2480-4.
10. Mukhtar K., Khattak I. Transversus abdominis plane block for renal transplant recipients. *Br J Anaesth.* 2010; 104: 663-4.
11. Niraj G., Searle A., Mathews M. et al. Analgesic efficacy of ultrasound-guided transversus abdominis plane block in patients undergoing open apendicectomy. *Br J Anaesth.* 2009; 103: 601-5.
12. Barrington M.J., Ivanusic J.J., Rozen W.M., Hebbard P. Spread of injectate after ultrasound-guided subcostal transversus abdominis plane block: a cadaveric study. *Anaesthesia.* 2009; 64: 745-50.
13. McDonnell J.G., O'Donnell B.D., Farrell T., Gough N., Tuite D., Power C., Laffey J. Transversus abdominis plane block: a cadaveric and radiological evaluation. *Reg Anesth Pain Med* 2007; 32: 399-404.
14. Tran T., Ivanusic J., Hebbard P., Barrington M. Determination of spread of injectate after ultrasound-guided transversus abdominis plane block: a cadaveric study. *Br J Anaesth.* 2009; 102: 123-127.
15. Murouchi T., Yamauchi M., Gi E., Takada Y., Mizuguchi A., Yamakage M., Fujimiya M. Ultrasound-guided subcostal and midaxillary transversus abdominis plane block: a cadaveric study of the spread of injectate. *Masui.* 2013; 62 (1): 60-63.

*Submitted 14.08.2017*

*Reviewer MD, prof. A. Zlotnik,  
date of review 04.09.2017*

**УДК 618.3-06:(616.12-008.331+661-005.98+616.8-009.24)-089.5-08-039.35**

**Я. М. Підгірний**

## **ДІАГНОСТИКА ТА ЛІКУВАННЯ СЕПСИСУ У ВАГІТНИХ І ПОРОДІЛЕЙ: ДИСКУСІЙНІ ПИТАННЯ НАСТАНОВИ “SURVIVING SEPSIS CAMPAIGN INTERNATIONAL GUIDELINES FOR MANAGEMENT OF SEPSIS AND SEPTIC SHOCK: 2016”**

*Львівський національний медичний університет  
імені Данила Галицького, Львів, Україна*

**УДК 618.3-06:(616.12-008.331+661-005.98+616.8-009.24)-089.5-08-039.35**

**Я. М. Підгірний**

### **ДИАГНОСТИКА СЕПСИСА У БЕРЕМЕННЫХ И РОЖЕНИЦ: ДИСКУССИОННЫЕ ВОПРОСЫ КЛИНИЧЕСКИХ РЕКОМЕНДАЦИЙ “SURVIVING SEPSIS CAMPAIGN INTERNATIONAL GUIDELINES FOR MANAGEMENT OF SEPSIS AND SEPTIC SHOCK: 2016”**

Физиологические показатели беременных имеют особенности, которые вносят свои коррективы в классическую картину диагностики и лечения сепсиса/септического шока в данной категории больных.

---

© Я. М. Підгірний, 2017